Specificity and sensitivity of a single CSF-restricted IgG band cut-off as a marker of Multiple Sclerosis

FRANCESCO ANTONIO LOSAVIO

OLIGOCLONAL BANDS (OCB) AND MS: A BRIEF SUMMARY OF THEIR HISTORY

WHAT OCB ARE?

Oligoclonal bands (OCB) are **immunoglobulins** detected in the serum and the CSF by isoelectric focusing (IEF) followed by immunoblotting. Finally, a comparison between the OCB found in the CSF and in the serum of the patient is made to determine the origin of the immunoglobulin bands.

OCB PATTERNS

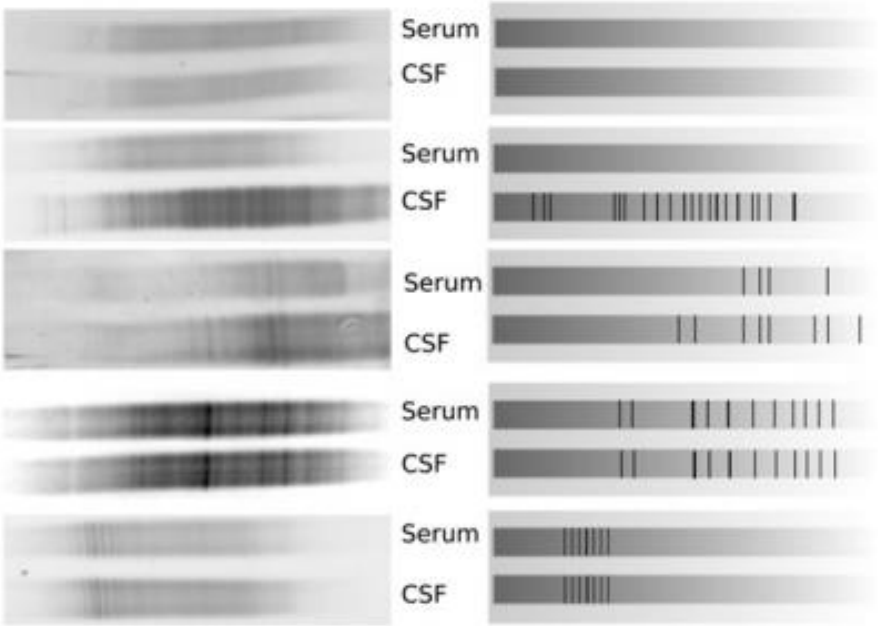

Petzold A. Intrathecal oligoclonal IgG synthesis in multiple sclerosis. Journal of Neuroimmunology (2017)

OCB AND MS

SPECIAL ARTICLE

New Diagnostic Criteria for Multiple Sclerosis: Guidelines for Research Protocols

Charles M. Poser, MD,[1] Donald W. Paty, MD,[2] Labe Scheinberg, MD,[3] W. Ian McDonald, FRCP,[4] Floyd A. Davis, MD,[5] George C. Ebers, MD,[6] Kenneth P. Johnson, MD,[7] William A. Sibley, MD,[8] Donald H. Silberberg, MD,[9] and Wallace W. Tourtellotte, MD[10]

OCB AND MS

Category	Attacks	Clinical evidence		Paraclinical evidence	CSF OCB/IgG[a]
A. Clinically definite					
CDMS A1	2	2			
CDMS A2	2	1	And	1	
B. Laboratory-supported definite					
LSDMS B1	2	1	Or	1	+
LSDMS B2	1	2		+	
LSDMS B3	1	1	And	1	+
C. Clinically probable					
CPMS C1	2	1			
CPMS C2	1	2			
CPMS C3	1	1	And	1	
D. Laboratory-supported probable					
LSPMS D1	2				+

Attack: The occurrence of a symptom or symptoms of neurological dysfunction, with or without objective confirmation, lasting more than 24 h constitutes an attack.
Clinical evidence: Signs of neurological dysfunction demonstrable by neurological examination. Such neurological signs are acceptable even if no longer present, provided that they were elicited and recorded.
Paraclinical evidence: CT or MRI scan, evoked potentials, induced hyperthermia or specific urological studies.

[a] CSF OCB/IgG = cerebrospinal fluid oligoclonal bands or increased intrathecal

OCB AND MS

SPECIAL REPORT

Recommended Diagnostic Criteria for Multiple Sclerosis: Guidelines from the International Panel on the Diagnosis of Multiple Sclerosis

W. Ian McDonald, FRCP,[1] Alistair Compston, FRCP,[2] Gilles Edan, MD,[3] Donald Goodkin,[4] Hans-Peter Hartung, MD,[5] Fred D. Lublin, MD,[6] Henry F. McFarland, MD,[7] Donald W. Paty, MD,[8] Chris H. Polman, MD,[9] Stephen C. Reingold, PhD,[10] Magnhild Sandberg-Wollheim, MD,[11] William Sibley, MD,[12] Alan Thompson, MD,[13] Stanley van den Noort, MD,[14] Brian Y. Weinshenker, MD,[15] and Jerry S. Wolinsky, MD[16]

OCB AND MS

Table 3. Diagnostic Criteria

Clinical Presentation	Additional Data Needed for MS Diagnosis
Two or more attacks; objective clinical evidence of 2 or more lesions	None[a]
Two or more attacks; objective clinical evidence of 1 lesion	Dissemination in space, demonstrated by MRI[b] *or* Two or more MRI-detected lesions consistent with MS plus positive CSF[c] *or* Await further clinical attack implicating a different site
One attack; objective clinical evidence of 2 or more lesions	Dissemination in time, demonstrated by MRI[d] *or* Second clinical attack
One attack; objective clinical evidence of 1 lesion (monosymptomatic presentation; clinically isolated syndrome)	Dissemination in space, demonstrated by MRI[b] *or* Two or more MRI-detected lesions consistent with MS plus positive CSF[c] *and* Dissemination in time, demonstrated by MRI[d] *or* Second clinical attack

OCB AND MS

Insidious neurological progression suggestive of MS	Second clinical attack Positive CSF[c] *and* Dissemination in space, demonstrated by 1) Nine or more T2 lesions in brain *or* 2) 2 or more lesions in spinal cord, *or* 3) 4–8 brain plus 1 spinal cord lesion *or* abnormal VEP[e] associated with 4–8 brain lesions, or with fewer than 4 brain lesions plus 1 spinal cord lesion demonstrated by MRI *and* Dissemination in time, demonstrated by MRI[d] *or* Continued progression for 1 year

OCB AND MS

Diagnostic Criteria for Multiple Sclerosis: 2005 Revisions to the "McDonald Criteria"

Chris H. Polman, MD, PhD,[1] Stephen C. Reingold, PhD,[2] Gilles Edan, MD,[3] Massimo Filippi, MD,[4]
Hans-Peter Hartung, MD,[5] Ludwig Kappos, MD,[6] Fred D. Lublin, MD,[7] Luanne M. Metz, MD,[8]
Henry F. McFarland, MD,[9] Paul W. O'Connor, MD,[10] Magnhild Sandberg-Wollheim, MD,[11]
Alan J. Thompson, MD,[12] Brian G. Weinshenker, MD,[13] and Jerry S. Wolinsky, MD[14]

OCB AND MS

Diagnostic Criteria for Multiple Sclerosis: 2010 Revisions to the McDonald Criteria

Chris H. Polman, MD, PhD,[1] Stephen C. Reingold, PhD,[2] Brenda Banwell, MD,[3]
Michel Clanet, MD,[4] Jeffrey A. Cohen, MD,[5] Massimo Filippi, MD,[6] Kazuo Fujihara, MD,[7]
Eva Havrdova, MD, PhD,[8] Michael Hutchinson, MD,[9] Ludwig Kappos, MD,[10]
Fred D. Lublin, MD,[11] Xavier Montalban, MD,[12] Paul O'Connor, MD,[13]
Magnhild Sandberg-Wollheim, MD, PhD,[14] Alan J. Thompson, MD,[15]
Emmanuelle Waubant, MD, PhD,[16] Brian Weinshenker, MD,[17] and Jerry S. Wolinsky, MD[18]

OCB AND MS

Insidious neurological progression suggestive of MS (PPMS)	1 year of disease progression (retrospectively or prospectively determined) plus 2 of 3 of the following criteria[d]: 1. Evidence for DIS in the brain based on ≥1 T2 lesions in the MS-characteristic (periventricular, juxtacortical, or infratentorial) regions 2. Evidence for DIS in the spinal cord based on ≥2 T2 lesions in the cord 3. Positive CSF (isoelectric focusing evidence of oligoclonal bands and/or elevated IgG index)

OCB AND MS

Diagnosis of multiple sclerosis: 2017 revisions of the McDonald criteria

Alan J Thompson, Brenda L Banwell, Frederik Barkhof, William M Carroll, Timothy Coetzee, Giancarlo Comi, Jorge Correale, Franz Fazekas, Massimo Filippi, Mark S Freedman, Kazuo Fujihara, Steven L Galetta, Hans Peter Hartung, Ludwig Kappos, Fred D Lublin, Ruth Ann Marrie, Aaron E Miller, David H Miller, Xavier Montalban, Ellen M Mowry, Per Soelberg Sorensen, Mar Tintoré, Anthony L Traboulsee, Maria Trojano, Bernard M J Uitdehaag, Sandra Vukusic, Emmanuelle Waubant, Brian G Weinshenker, Stephen C Reingold, Jeffrey A Cohen

OCB AND MS

MULTIPLE SCLEROSIS JOURNAL | MSJ

Letter

Oligoclonal bands do not represent dissemination in time in the 2017 revisions to the McDonald criteria

WHEN ARE OCB POSITIVE?

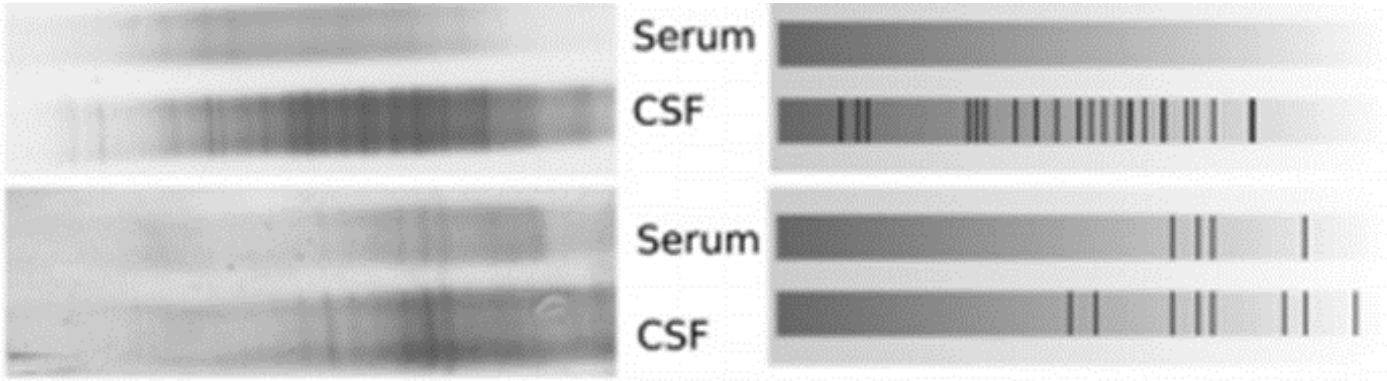

AIMS

We retrospectively analyzed the results of the OCB search in a cohort of 1125 patients to determine their sensitivity and specificity in the diagnosis of MS and the impact of a single CSF-restricted IgG band cut-off to these parameters.

RESULTS

Multiple Sclerosis	627
NMO and NMO-SD	11
Other inflammatory disease of the CNS	154
Peripheral nerves inflammatory disease	73
Non-inflammatory neurological disease	189
Symptomatic controls	21
CNS tumors	34
CNS infections	16

RESULTS

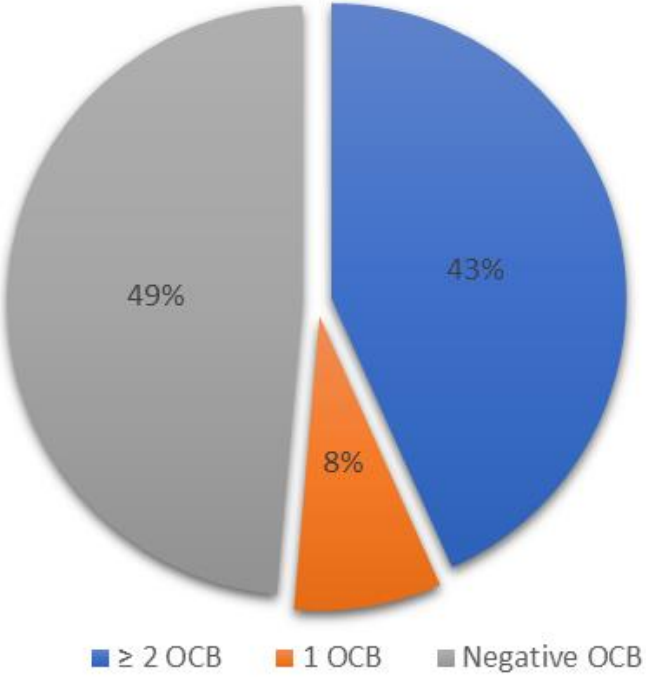

≥ 2 OCB	487
1 OCB	91
Negative OCB	547

SPECIFICITY AND SENSITIVITY WITH A ≥ 2 BANDS CUT-OFF

	SM	Non SM
BOG+	457	30
BOG-	170	468

SENSITIVITY : 72.9 %

SPECIFICITY: 94.0 %

SPECIFICITY AND SENSITIVITY WITH A ≥ 1 BANDS CUT-OFF

	SM	Non SM
BOG+	523	56
BOG-	103	443

SENSITIVITY : 83.4 %

SPECIFICITY: 89.0 %

SINGLE BAND FINDINGS

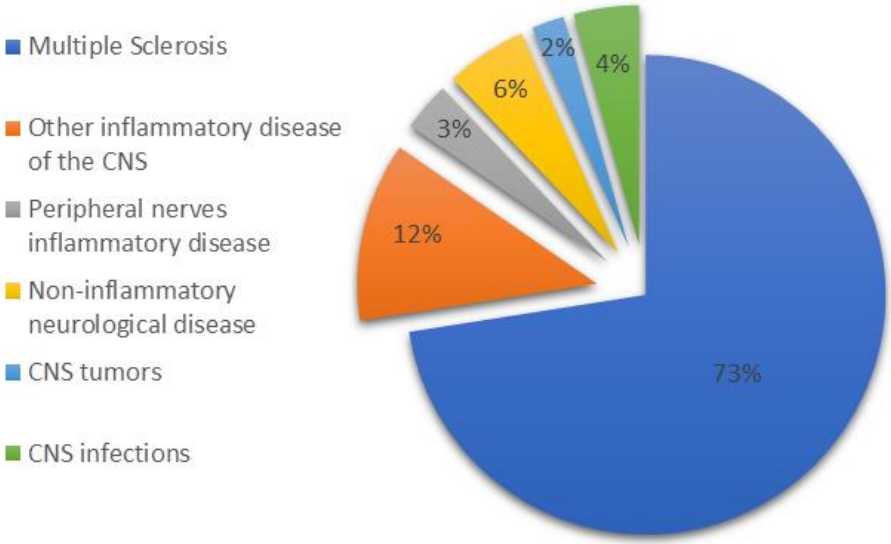

Multiple Sclerosis	66
NMO and NMO-SD	0
Other inflammatory disease of the CNS	11
Peripheral nerves inflammatory disease	3
Non-inflammatory neurological disease	5
Symptomatic controls	0
CNS tumors	2
CNS infections	4

POSITIVE PREDICTIVE VALUE: 72.5 %

CHANGING IN THE SENSITIVITY AND SPECIFICITY FOR MS WITH A SINGLE BAND CUT OFF

DOUBLE BAND		SINGLE BAND
SENSITIVITY : 72.9 %	+ 10.5% →	SENSITIVITY : 83.4 %
SPECIFICITY: 94.0 %	- 5.0% →	SPECIFICITY: 89.0 %

CONCLUSIONS

In case of a clinical hypothesis of MS, the presence of a single CSF-restricted IgG band, could be supportive for MS diagnosis.


Thank
You