I.R.C.C.S. Ospedale San Raffaele

DIVISION OF NEUROSCIENCE

INSTITUTE OF EXPERIMENTAL NEUROLOGY

NRU

Spinal cord atrophy in Neuromyelitis Optica is spatially related to cord lesions and clinical disability

[1,2]L. Cacciaguerra, [1]P. Valsasina, [2] V. Martinelli, [1,2]M.A. Rocca, [1,2]M. Filippi

[1]Neuroimaging Research Unit, and [2]Department of Neurology, Institute of Experimental Neurology, Division of Neuroscience, San Raffaele Scientific Institute, Vita-Salute San Raffaele University, Milan, Italy.

BACKGROUND / Clinical considerations

M. E. Devic, de Lyon. — **Myélite aiguë dorso-lombaire avec névrite optique. — Autopsie.** 1894

Core clinical characteristics

1. Optic neuritis
2. Acute myelitis
3. Area postrema syndrome: episode of otherwise unexplained hiccups or nausea and vomiting
4. Acute brainstem syndrome
5. Symptomatic narcolepsy or acute diencephalic clinical syndrome with NMOSD-typical diencephalic MRI lesions (figure 3)
6. Symptomatic cerebral syndrome with NMOSD-typical brain lesions (figure 3)

Additional MRI requirements for NMOSD without AQP4-IgG and NMOSD with unknown AQP4-IgG status

1. Acute optic neuritis: requires brain MRI showing (a) normal findings or only nonspecific white matter lesions, OR (b) optic nerve MRI with T2-hyperintense lesion or T1-weighted gadolinium-enhancing lesion extending over >1/2 optic nerve length or involving optic chiasm (figure 1)
2. Acute myelitis: requires associated intramedullary MRI lesion extending over ≥3 contiguous segments (LETM) OR ≥3 contiguous segments of focal spinal cord atrophy in patients with history compatible with acute myelitis (figure 1)
3. Area postrema syndrome: requires associated dorsal medulla/area postrema lesions (figure 2)
4. Acute brainstem syndrome: requires associated periependymal brainstem lesions (figure 2)

Wingerchuck et al., Neurology 2015

Asymptomatic myelitis in neuromyelitis optica and autoimmune aquaporin-4 channelopathy

Flanagan et al., Neurology 2015

Recovery

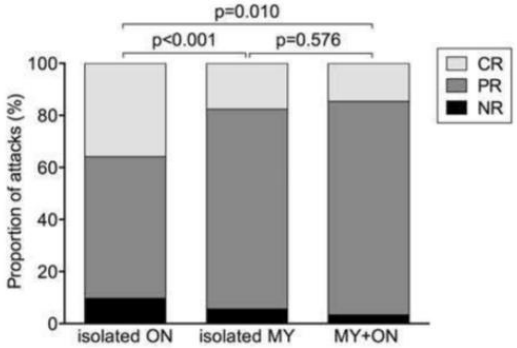

	isolated ON	isolated MY	MY+ON
Complete remission	89 (35.9%)	91 (17.6%)	13 (14.6%)
Partial remission	135 (54.4%)	397 (76.8%)	73 (82.0%)
No remission	24 (9.7%)	29 (5.6%)	3 (3.4%)
Number of attacks	248	517	89

Kleiter et al., Ann Neurol 2016

Secondary progression (6.1 Y FU)

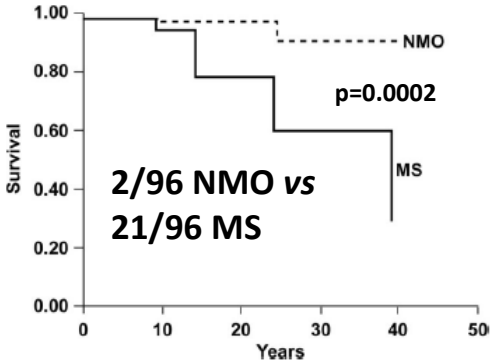

Wingerchuk et al., Neurology 2007

BACKGROUND / MRI evidence

Lesions

- **≥3 vertebral segments** (Wingerchuk et al, Neurology 2015)
- **Cervical and thoracic levels** (Tatekawa et al., AJNR 2018)
- Centrally located in the **GM** (Ciccarelli et al., Lancet Neurol 2019, Nakamura et al., J Neurol 2008)

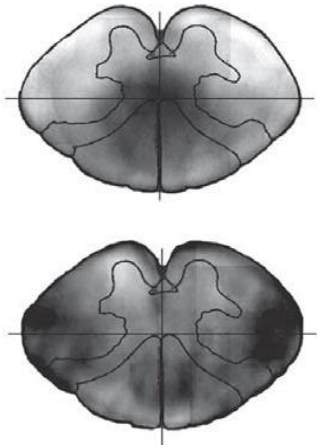

NMO

MS

Atrophy

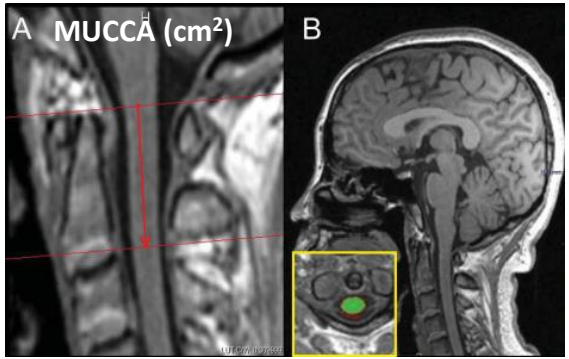

NMO lower than HC <0.05

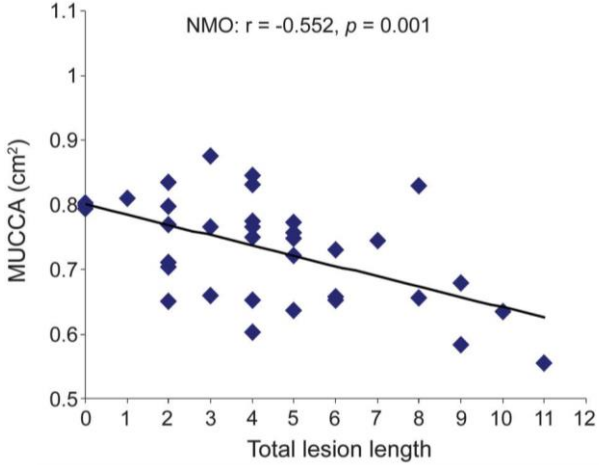

Liu et al., Neurology 2015

AIMS

- The direct spatial relationship between focal lesions and atrophy has never been explored in NMO

We aimed to characterize the spatial distribution of T1-hypointense spinal cord lesions in a cohort of 52 aquaporine-4 (AQP4)-IgG positive NMO patients and its association with spinal cord atrophy and clinical disability

METHODS

- **MRI sequences**: 3.0 T cord 3D T1-weighted scans
- **Atrophy quantification**:
  - **Cross-sectional area (CSA)** of cervical and upper portion of the dorsal cord (until D3) was measured as the total cord volume divided by the cord length (using the active surface method) and normalized by the brain scaling factor
  - Cord atrophy was compared between **52 NMO and 28 age-matched HC**

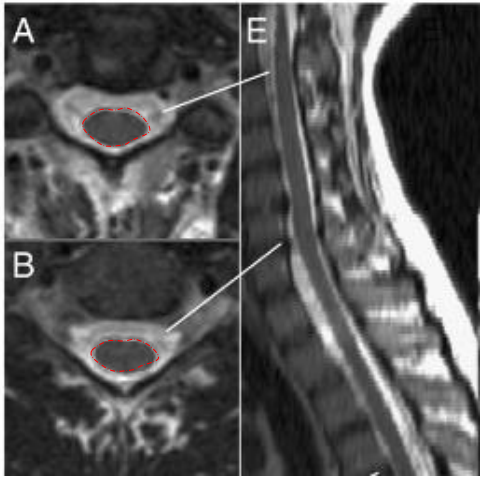

Horsfield et al., Neuroimage 2010

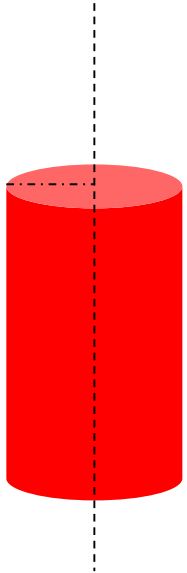

METHODS

- **Gray matter (GM) and white matter (WM) spinal cord lesion assessment**:
  - Voxel-wise lesion probability maps (LPMs) were obtained from manual segmentation of **3D T1-weighted scans**
  - **LPMs** and straightened cord lesion masks were superimposed to a custom-made region-label template, obtained by warping in our template space the *a priori* GM probability and cord level maps from the spinal cord toolbox

RESULTS

Clinical variables

	NMO (n=52)	HC (n=28)	p
Mean age (SD) [years]	44.3 (14.5)	43.6 (12.5)	0.82*
Males/Females	7/45	12/16	**0.005^**
Median disease duration (IQR) [years]	3.9 (1.6-10.7)	-	-
Median EDSS (IQR)	4.5 (2.5-8.0)	-	-
Median number of myelitis (range)	2.0 (0-14)	-	-

*t-test; ^Pearson's χ2 test; +Mann-Whitney test.

Brain MRI variables

	NMO (n=52)	HC (n=28)	p
Median brain T2 LV (IQR) [ml]	0.37 (0.07-2.12)	0.00 (0.0-0.2)	**<0.0001+**
Median brain T1 LV (IQR) [ml]	0.08 (0.0-0.8)	0.00 (0.0-0.0)	**0.001+**
Mean NBV (SD) [ml]	1462 (93)	1532 (96)	**0.002***

Spinal cord MRI variables

Median n° of spinal cord lesions (IQR)	1 (0-3)	-	-
Median T1 LV (IQR) [ml]	0.43 (0.0-0.1)	-	-
Mean CSAn (SD) [mm^2]	98 (16)	101 (11)	0.31*

RESULTS / Lesions



White matter

Grey matter

De Leener et al., 2016

	Mean raw LV (SD) [ml]			Fractional lesion volume (FLV) [%] (SD)		
	GM	WM	p*	GM	WM	p*
C1	0.109 (0.14)	0.164 (0.23)	0.21	22.16 (29.0)	6.42 (8.9)	**0.002**
C2	0.082 (0.08)	0.136 (0.18)	0.10	26.74 (27.5)	9.61 (12.7)	**0.001**
C3	0.101 (0.11)	0.160 (0.22)	0.15	28.80 (32.2)	10.06 (14.1)	**0.001**
C4	0.102 (0.12)	0.154 (0.23)	0.20	25.82 (29.6)	8.92 (13.1)	**0.002**
C5	0.063 (0.08)	0.108 (0.17)	1.15	21.21 (27.4)	7.74 (12.13)	**0.006**
C6	0.051 (0.08)	0.064 (0.13)	0.59	16.81 (25.6)	5.17 (10.2)	**0.010**
C7	0.034 (0.07)	0.06 (0.13)	0.30	14.23 (28.6)	4.75 (10.5)	0.058
T1	0.051 (0.09)	0.084 (0.15)	0.25	19.11 (32.3)	5.73 (10.4)	**0.018**
T2	0.065 (0.09)	0.107 (0.18)	0.20	27.61 (37.6)	7.53 (12.8)	**0.003**
T3	0.070 (0.09)	0.103 (0.16)	0.27	29.26 (38.0)	7.20 (11.3)	**0.001**

* two-sample t-test

RESULTS / Lesions

p values

Level	Mean LV (SD) ml	AP	C1	C2	C3	C4	C5	C6	C7	T1	T2	T3
AP	0.069 (0.14)	-	0.02	0.17	0.03	0.04	0.57	0.68	0.42	0.94	0.56	0.56
C1	0.136 (0.19)	-	-	0.24	0.81	0.72	0.03	0.001	<0.0001	0.003	0.032	0.032
C2	0.109 (0.14)	-	-	-	0.35	0.42	0.32	0.028	0.008	0.07	0.33	0.33
C3	0.131 (0.18)	-	-	-	-	0.91	0.054	0.002	<0.0001	0.007	0.06	0.06
C4	0.128 (0.18)	-	-	-	-	-	0.07	0.003	0.001	0.01	0.07	0.07
C5	0.081 (0.13)	-	-	-	-	-	-	0.23	0.1	0.43	0.98	0.98
C6	0.058 (0.10)	-	-	-	-	-	-	-	0.64	0.68	0.22	0.22
C7	0.047 (0.10)	-	-	-	-	-	-	-	-	0.38	0.09	0.09
T1	0.067 (0.12)	-	-	-	-	-	-	-	-	-	0.42	0.42
T2	0.086 (0.14)	-	-	-	-	-	-	-	-	-	-	0.99
T3	0.086 (0.13)	-	-	-	-	-	-	-	-	-	-	-

ANOVA

Volume affected by lesions [%]

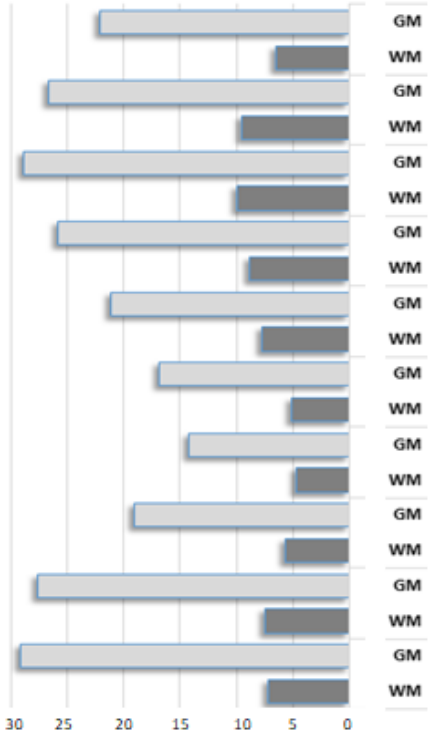

RESULTS / Atrophy

Spinal cord level	Cluster extent	t value		p
AP	137	4.05		<0.0001
C2-C4	2196	C2	5.04	0.04*
		C3	5.49	0.01*
		C4	4.69	<0.0001
T1-T3	2698	T1	5.11	0.03*
		T2	5.73	0.004*
		T3	4.55	<0.0001

*FWE corrected p

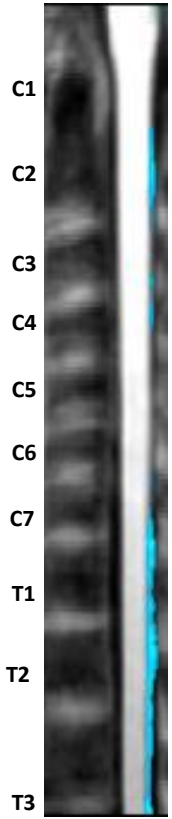

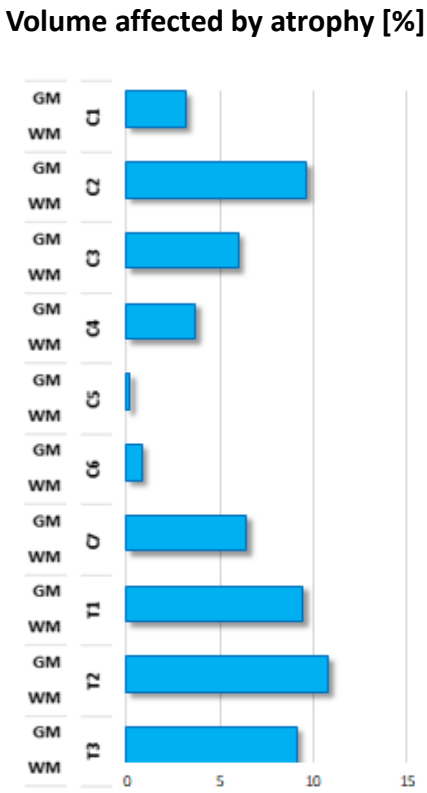

RESULTS / Correlations

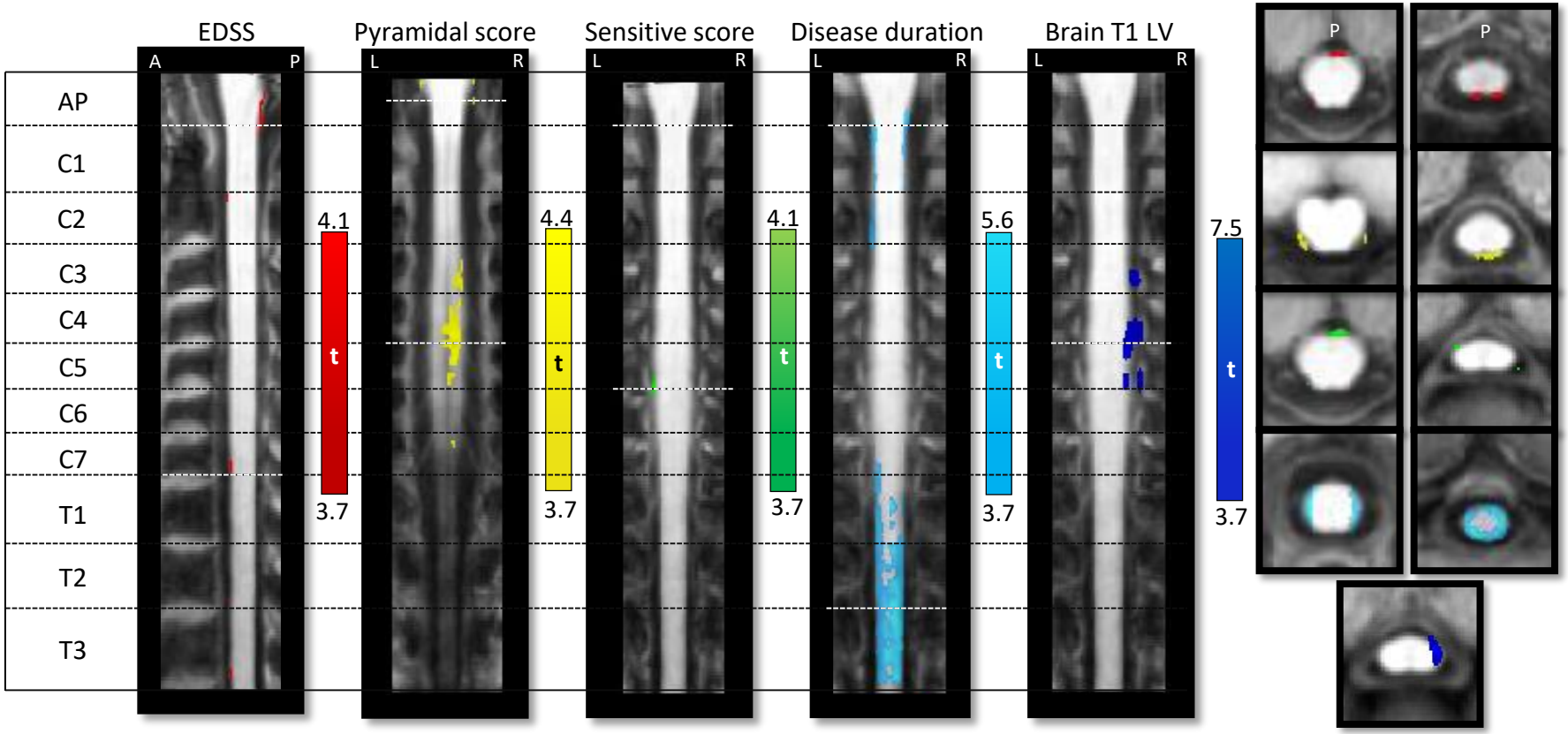

CONCLUSIONS

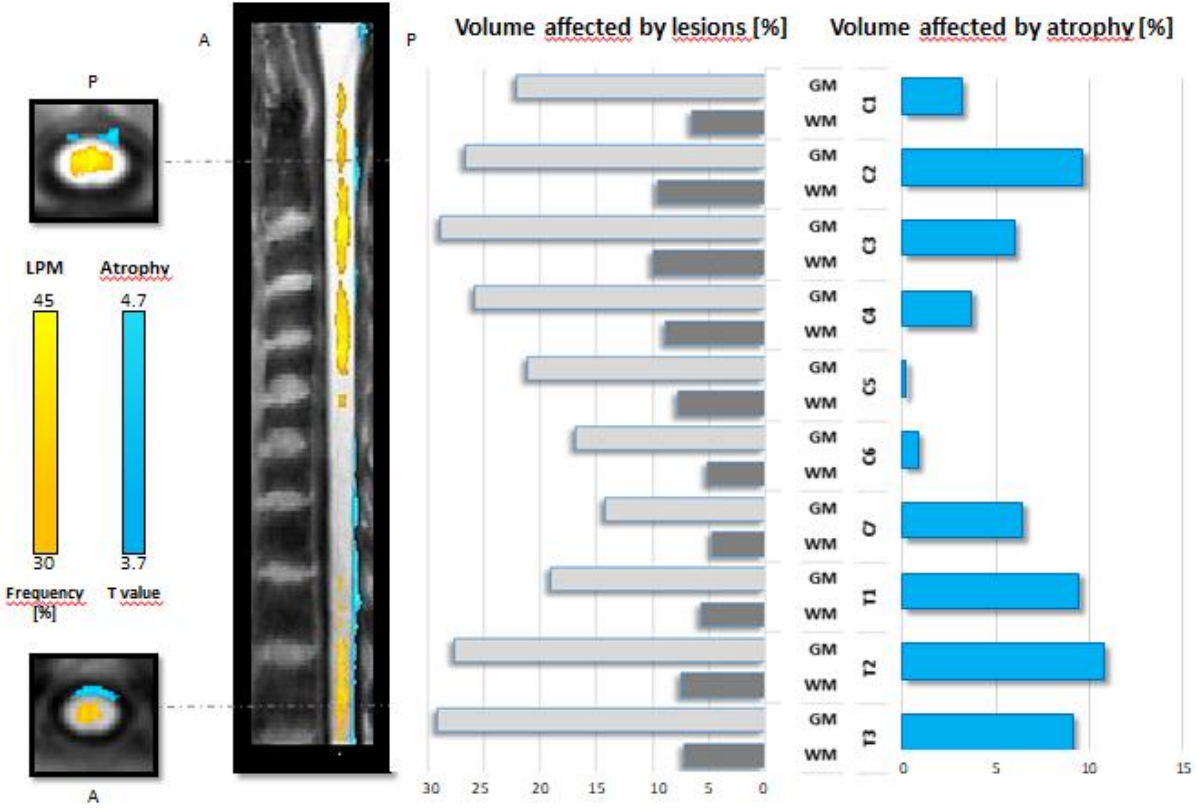

CONCLUSIONS

- In NMO, we found a preferential tropism of spinal cord lesions for the GM and higher involvement of the upper cervical and upper thoracic segments
- Differently from MS, NMO cord atrophy seems related to the occurrence of spinal cord lesions and not to a more diffuse damage
- Such an evidence suggests the existence in NMO patients of a focal, inflammatory-driven mechanism of damage rather than a primary neurodegenerative and diffuse process
- Atrophy measures are strongly correlated with global EDSS and its subscores, suggesting that an highly effective treatment could prevent disability accrual in NMO